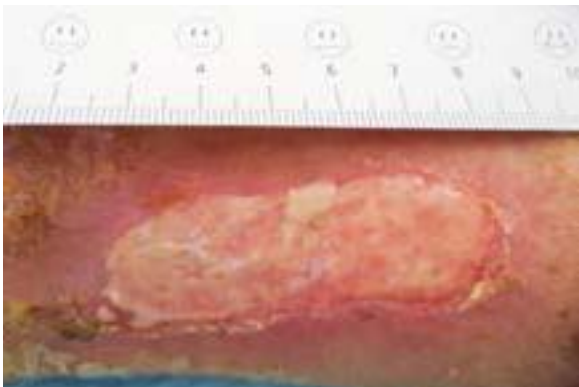


HydroTherapy

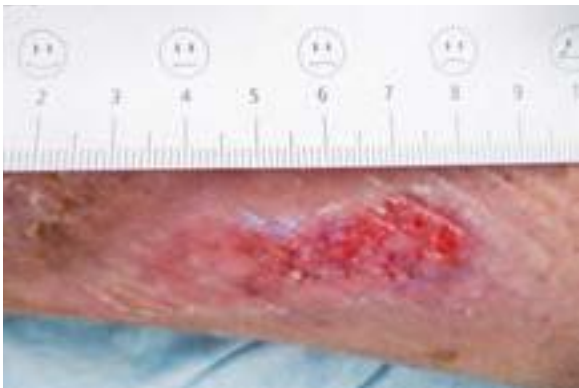Case studies

Case 2: Patient, male, 78 years old

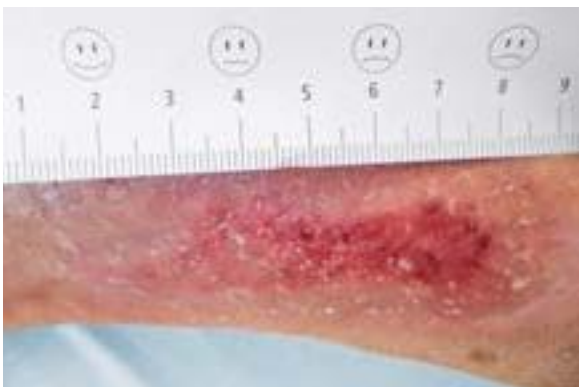Description of wound: A small infectious ulceration, on right medial lower leg, treatment started with HydroClean® plus, 4 cm, round, followed by HydroTac® 10×10 cm, fixing with Peha-haft®, observation period: 31.10.2013–26.11.2013



1. 31.10.2013
HydroClean® plus 4 cm round



2. 08.11.2013
HydroClean® is removed and
changeover to HydroTac® is
carried out.



3. 26.11.2013
The aim of the therapy was
achieved after changing dressing
seven times.

HydroTherapy
Efficacy. And Simplicity.

